

The effect of uranyl acetate toxicity in the tissues of the heart, Liver, kidney and blood physiological & biochemical Parameters in male rabbit's

Nael M. S. AL-Hamzawy

Medicine C./ AL-Muthanna Uni.

Email : Nael.serheed@yahoo.com

Abstract

The aim of current research to study changes in some tissues and physiological and biochemical blood tests resulting from the effect of the uranyl acetate toxicity with using concentrations (25,35) mg/kg represent in high rates as one of the salts of uranium, spreading in some endemic areas with this toxic and radioactive substance. The study included 18 animals of local's rabbits ,which were divided into three groups, the control group: that was treated orally 1 ml \ kg of Physiological salt solution (Normal Saline) during the trial period amounting one month (30 days),The first group: treated 25 mg \ kg of body weight of the animal the length of the experiment, The second group was treated 35mg\ kg of body weight during the experiment.

The results of the experiment Showed that there was a significant decrease ($P < 0.05$) in red blood corpuscles count (RBCc) and Packed cells volume (PCV), while there was a significant increase in both the amount of Hemoglobin (Hb) and white blood cells count (WBCc) in comparison with control group. As for the results of biochemical blood tests have revealed the existence of a significant increase ($P < 0.05$) in the amount of triglycerides(TG), cholesterol (S.Chol), urea (Urea), creatinine (Creat.) in the blood, also appeared significant increase in the proportion of functions enzymes of the liver (ALT, AST) and the amount of sugar(Glucose) in the blood of animals in the two treatments groups, while there was a significant decrease ($P < 0.05$) in the amount of total protein (T.Protein) in the blood of treated animals when compared to the control group of the two groups also.

The microscopic examination of sections showed cardiac muscle tissue an dilation and flayed in the lining of the blood vessel and the relapse of the nuclei of cells with the appearance of die cellular lysis of the parts of cells, as shown in the second group changes the biggest was the appearance of large hemorrhage to red blood cells (RBC) in the blood vessel and spread of these corpuscles between the cells with a total damage of the tissue. The histological sections of liver showed revealing narrowing of the central vein, bleeding of erythrocytes (RBCs), damage to cell membranes and conglomerate nuclei, with the large congestion in central vein with RBC and the cells die and the appearance of inflammatory cells (Pus Cells). While the sections of kidney showed conglomerate in glomerulus and flayed the lining of Bowman's capsule with the expansion of tubular tract and found to dead cells, In an increase of the concentration of acetate has been damaged completely fitting histological kidney with stenosis

significantly proximal tubule and expansion in the blood vessel and the emergence of erythrocytes (RBC) and inflammatory cells (Pus Cells).

It can be concluded that the entry of high concentrations of uranium or one of its salts to the body or even exposure in endemic areas to this substance lead to healthy effects and significant side can be considered very dangerous to the life of the organism marked by changes in the structures and functions of the body organs, which indicated the healthy ill cases that led to it the high concentrations used in the experiment after exposure of animals, so it must caution strongly of the seriousness of this substance.

Keywords \ Uranyl acetate, Toxicity, Histological sections, Blood criteria, Male rabbits .

Introduction

Uranium is a heavy metal white silver medal metallic radiant, analysis to give alpha particles ⁽¹⁾, is found naturally in many parts of the world, as there is in the soil, water, air, plants and animals, and there is also high concentrations in volcanic rocks and igneous rocks, in addition to its presence in the body in human skin , nails, teeth and hair ^(2,3), and there are also uranium in ground water and rock phosphate and carbonate deployed in the western regions , medium and southern of Iraq, which up of (20-300) ppm^(4,5,6,7). The study of uranium concentration in the soil of some of the cities and provinces of Iraq, showed the presence of the highest in the province of Muthanna, and that up to 7.8 ppm and followed by Dhi Qar and Basra, gradually, and generally had concentrations of uranium highest levels near the soil surface⁽⁸⁾, and metal contamination found in food that is grown in Iraq, which exceeded the levels permitted by the World Health Organization in some areas and has now become a major concern about the presence of depleted uranium in Iraq. And that some areas of Iraq significantly contaminated with toxic metals and various radioactive contamination in water, air and soil so you must search for certain mechanisms to reduce the threat to human, from these mechanisms the plants that remove or stabilize metal contaminants ^(9,10).

Uranium exposure could lead to different effects, as in other chemicals, but in particular to poisoning the kidneys, and can be caused by this poisoning by breathing air that contains uranium dust or by eating substances containing uranium and its entry into the stream blood ⁽¹¹⁾, In addition to the inhalation of tobacco or tobacco products that were planted and were grown using phosphate fertilizer, or even of food and drinking water containing a quantity of uranium more than the allowable limit of Tell the World Health Organization. The people are exposed to uranium per day through food and water and that up to (0.07 - 1.1) micrograms and in various forms ⁽¹²⁾.

In one of the studies on the internal organs of sheep in some Iraqi cities showed that the amount of uranium varies in its rate in the organs of the body, which showed the highest rate in the trachea and less in the lung, followed by the liver, which showed the proportion of convergent with the heart, and

attributed the reason for the increase of uranium in some areas to soil contaminated with uranium and move to leaves and grass vegetation down to the bodies of the animals there ⁽¹³⁾, and that the amount of uranium estimated in the human body up to 40 mg, which are distributed approximate 40% in muscle, 0.20% in the skeleton, 0.10% in the blood, 0.4% in the lung, 0.1% in the liver and 3% in the kidneys ⁽¹⁴⁾.

The absorption of uranium through the intestinal gut depends on the melting compound depleted uranium previously by food and oxidizing agents accompanying such as iron, which increases the rate of absorption of uranium ⁽¹⁵⁾, and that the rate of absorption of the digestive tract in humans are (1-2%) of Total enters into the body ^(17,16). Upon entering uranium human body through water or food is to take it out through the feces by 90%, and the amount ingested it enters the blood and raised mostly through the urine within a few days, while the amount ingested and the remaining in the body is deposited in bones and show effects of toxic and radioactive over time ⁽¹²⁾, Alpha particles (α) radiation emitted by the intervention of uranium is about 30 micrometers in soft tissue and thus be unable to penetrate the surface layer of dead skin. The beta particles (β) have the greater ability to penetrate the skin, while a vulnerability is very high for particles gamma (γ) and thus are the most dangerous species ⁽¹⁸⁾, and that the seriousness of these objects come from the ionizing radiation of energy, which is transmitted to the living material in the body of the object neighborhood and falls within the molecular interactions and the genetic material of living (nucleic acids) leading to genetic damage and changes ⁽¹⁹⁾.

The large danger for the uranium from the damage toxic for Kidneys, in addition to the incidence of cancer, especially in the bones and liver, and cause different blood diseases including leukemia, as well as lung cancer ⁽¹²⁾. Mentioned some studies that the limit to exposure of uranium in the United States 30 micrograms per liter in places where there is much uranium industrially ^(11,20), and very high concentrations of uranium and up (50-150 mg) can cause serious illness in the body compared to low concentrations (25-40 mg), which lead to different symptoms ⁽¹²⁾.

The uranyl acetate is one of salt compounds of uranium, which is the most common vehicles associated with the uranyl oxygen as ion composed of UO_2 and (U234, U235, U238), which is working on the emissions of alpha and gamma of them ⁽²⁰⁾.

Materials & Methods

1- The Experimental Animals

In the current experiment 18 of local rabbits (*Oryctolagus cuniculus's*), were used they were distributed to three groups by 6 animals per group, were the ages of animals ranging from one year to one year and almost four months, and weights ranging between (1100-1750 g) almost, left the animals for a period of one week to adapt on the circumstances before treatment, was to take care of their cleanliness and fed constantly and conditions are similar of temperature, Light, drinking water and the length of the trial period for 30 days, then was to create concentrations required material of uranyl

acetate by a series of dilution, after it has been treated animals as following:- Control group : where was treated orally using a metal tube manufactured for this purpose the physiological salt solution (0,9) Normal Saline (1ml) per kg of body weight per day duration of the experiment, The first group : where animals have been dosage textured water concentration of uranyl acetate (25 mg) per kg of body weight per day duration of the experiment, The second Group : where animals treated concentration (35 mg) per kg of body weight per day length of the experiment.

2- Histological study

Conducted cutting process for tissues of the studied organs (heart , liver and kidney) in method ⁽²⁸⁾.

3- Blood tests

The proportion of Packed cells volume (PCV) and Blood Hemoglobin (Hb) were measured ⁽²¹⁾, in addition to the number of Red blood cells count (RBCc) and White blood cells count WBC in method ⁽²²⁾, while the Biochemical blood tests, were measured Blood Sugar , Blood Urea and Creatinine manner according to ⁽²³⁾, while the measurement of Serum Cholesterol and the amount of Triglycerides (TG) according to ⁽²⁴⁾, while the rates of liver enzymes(ALT, AST) has been measured ⁽²⁵⁾, and was measuring the amount of Total protein in the blood of animals in ⁽²¹⁾.

4- Statistical analysis

Statistical analysis was conducted using SPSS program and the level of probability of 0.05, then find differences of Statistical compared between treatment groups with control group using T-test⁽²⁶⁾.

Results & Discussion

1- Physiological Tests

The statistical results for physiological blood parameters (Table 1) showed there was a significant decrease ($P < 0.05$) in packed cells volume (PCV) of the two groups , as well as a significant decrease in the red blood cells count (RBC) in the second group only for animals treated with uranyl acetate material when compared to the control group, while show significant increase in the amount of hemoglobin blood (Hb) in the second group only with a slight increase did not reach the level of significantly of the first group when compared to the control group. The results also showed significant increase ($P < 0.05$) in the white blood cells count (WBC) in the blood of the treated rabbits in the two groups when comparing with control group (Table 1). Some researches has shown that dealt with uranium contamination led to changes in the proportions of the blood parameters of animals after exposure, Represented with decrease of RBC count with a note an increase in the WBC count ⁽²⁷⁾, and attributed the reason for these changes to the physiological parameters that uranium absorbed and remaining in the body is deposited in bones and show toxicity effects in the bone marrow, which differs functionally in producing types of blood cells⁽¹²⁾, in addition to the damage in the tissues of the liver and kidney that was evident in this study, which may have led to confusion in the proteins synthesis Including globin and erythropoietin responsible for stimulating the production of RBC with increased WBC as a result of inflammatory

processes in the body tissue⁽²⁹⁾. The presents results also revealed that the uranium emergence in the blood is rapidly after swallowed and that appears to associate to the RBC, which are familiar with later complexes with these corpuscles lead to put outside the body, leading to a decline in the number of RBC and the proportion of packed cells volume generally ⁽³⁰⁾, in addition to what was said ⁽³¹⁾ that exposure to high concentrations of acetate enrichment leads to weakness of the process of Erythropoiesis in the bone marrow as a result of the lack of manufacturing the hormone erythropoietin in kidney affected, as well as a result of the levels decline of mRNA in the receptor cells for this hormone in the bone marrow with a note increase RBC break, which produced a small number of these corpuscles and reduced PCV in the blood of mice treated in this substance. This study was consistent with what was said⁽³²⁾ that exposure to uranyl acetate latest significant decrease in the number of RBC and an increase in the amount of Hb treatment mice, as well as agreed ^(13,33) with what they referred to that the uranium leads to a reduction in PCV and increase WBC count, while not agree with this research in decrease of Hb amount and RBC increase.

2- Biochemical Tests

The results of the biochemical tests (Table 2) showed a significant increase ($P < 0.05$) in the amount of triglycerides(TG) and blood cholesterol of the first group and the second group when compared to the control group, has attributed the rise to changes in the liver tissue after treatment with uranyl acetate and to the changes in the rate of lipid metabolism and concentrations in the blood⁽³⁴⁾, and thus the lack of the ability of the liver to maintain the balance of through reduced fatty ability to remove Chylomicron particles from the bloodstream and inhibiting an lipoprotein Lipase enzyme, who works on the analysis of fat Which led to high cholesterol and fat triglycerides^(35,36), as reported by other research that uranyl acetate is working on the occurrence of oxidative stress to the liver cells, which makes them unable to fat metabolize causing an increase concentration in the bloodstream⁽³⁷⁾. In addition it may be the reason for the increase is the lack of production of the insulin hormone after damage in the beta cells in the pancreas which is responsible for stimulating the lipoprotein lipase enzyme that responsible for the separation of cholesterol compounds and lipoprotein in the blood and transported to the liver for disposal when the increase in the concentration ⁽³⁸⁾.

Also the results showed a significant increase ($P < 0.05$) in the amount of urea and creatinine in the blood of animals treated in the two groups when comparing a control group, where the researchers reported in the effect of uranyl acetate that this substance has a significant effect on the of blood biochemical parameters induced wide effect on body tissue, and came in some of the research that the treatment of this substance led to an increase in the rates of urea and creatinine and attributed the reason to the histological changes in the composition of the kidney, which was evident in this study also represents damage and harmed to tissues , in addition to the large disability in renal function, which led

to increase the amount of urea and creatinine in the blood of animals^(39.12), He added researches^(41.40) the exposure to uranium in mines led to a rise in the proportion of urea and blood Creatinine among workers as a result of necrosis of renal tubule cells and damage to the installation and glomerular filtration which produced of weakness in the kidney tissue. This study did not agree with what was said (42) that exposure to uranyl acetate lead to a decrease in the concentration of urea and creatinine in the blood.

Add to that the statistical results showed that the percentage of functions enzymatic of the liver (AST,ALT) found significantly increase when compared to the control group for the two groups. The increase in the concentration of these enzymes associated with a lot of damage in the liver tissue⁽²⁹⁾, which was evident in this study, and that this increase may be associated to the dissolution of the cells as a result of the accumulation of uranium salts transmitted through the blood to the tissues in this organ⁽⁴³⁾.

As regards the proportion of glucose has also appeared significant increase ($P < 0.05$) in the blood of the first and second groups of treated rabbits, While show significant decrease in the amount of total protein(T.Protein) for treated animals groups when compared to the control group (Table 2). The rise in the proportion of blood glucose may be due to the lack of production of the insulin hormone from the beta cells in the pancreas, which greatly affected by uranyl acetate substance and this is the main reason for the rise in blood sugar in experimental animals^(44.46), and this result is consistent with what was said by⁽⁴⁷⁾ the uranium is working to increase the level of sugar in the blood. either the decrease in total protein may be due to liver damage, which is the mainstay in the synthesis of proteins, which led to the accumulation in complexes with stable albumin⁽⁴⁸⁾, and the decline may be due to the interaction of uranium salts with albumin, which produced stable complexes in the blood serum of laboratory animals led to a decline in the proportion of total protein⁽⁴⁵⁾. Not consistent a result of the current study with what was said⁽⁴²⁾ that the uranyl acetate treatment leads to decrease of glucose concentration and an increase in the amount of total protein in the blood.

Agreed this study with research that reported that treated with uranyl acetate led to an increase in the concentration of cholesterol and triglycerides, blood urea, and a decrease in the proportion of total protein in mice treated with this substance^(50.49), while not agree with some of the research which reported that the high concentrations of this substance led to a decrease in the proportion of function enzymes of the liver and the amount of cholesterol and an increase in total protein in the blood of animals after exposure to this substance^(52.51).

3- Histological Study

A- The heart

Through microscopic examination of cross sections in the control group found that the heart muscle is composed of circular structures represent Cardio muscular cells exist including some of the large blood vessels, shows nuclei of cells in the center of some of the cells but not all because of the different levels in longitudinal order. either in longitudinal sections are shown of the heart muscle of longitudinal parallel and branched cells its related points represent to intercalated discs , which are not clear at staining by hematoxylin and Eosin stains, show nuclei of cells oval in the center of the cell (Pictures1). showed histological sections in first group animals some changes in the composition of the heart muscle represent in the cross-section the occurrence of expansion and sloughing of the lining of the blood vessel and relapse of the nuclei of some cells , in addition to show dead cells and change the overall shape of the tissue , either in the longitudinal section which showed irregular cells in parallel and the emergence of the decomposition of some parts of the muscle cells, in addition to changing the shape of the tissue of branching (Pictures 2). But when used a higher concentration of acetate substance in the second group showed the presence of hemorrhage of red blood cells (RBC) in the blood vessel and the spread of these corpuscles between cells, also found alienation of some of the lining of the vessel and the emergence of a relapse of the nuclei of cells in cross-section, in the longitudinal section appeared complete damage to myocardial tissue and the entire demise in the branching of muscle fiber, in addition to the decomposition of cell membranes and out of the nuclei (Pictures3).Found some researchers that the treatment with uranyl acetate lead to damage in many tissues in the body after penetrate the salts to its and move this material to the rest of the body parts reasoned great harm to organs that pass by, including the heart muscle ^(45,53), as stated ⁽⁵⁴⁾ that the acetate uranium material lead to damage to the histological structure to the heart muscle and die for some cells with some changes in the nuclei of cells. Did not consistent as a result of microscopic examination of heart muscle sections with what was said ⁽⁵⁵⁾ that treated with uranyl acetate in mice did not lead to histological changes in the heart and cardiovascular system in general.

B- The liver

Showed the histological sections for the livers of animals in the control group it consists of hexagonal structures stationed by Central Vain, which around him arranged hepatocytes in radial shape, which is separated from each vessels Sinusoids, while located Portal Vein between the hexagonal lobules (Picture 4). Either histological sections for livers in animals treated with uranyl acetate in the first group have shown there has been some narrowing in the central vein and the emergence of some of RBC and inflammatory cells in it with damage to some cells membranes, in addition to the conglomerate of decaying nuclei of cells with each other near the central vein, with preservation of the radial

distribution of hepatic cells in general (Picture 5). While showing the increase in the concentration that used from uranyl acetate in the second set and the presence of large congestion in the central vein and the emergence of a large amount of RBC in it and the little ones in decaying sinusoids, in addition to large died for cells and analyzed for the cellular membranes clearly with a note of inflammatory cells (Pus Cells) spread and damage to entire of hepatic tissue(Picture 6). The liver is organ of President to remove toxic substances from the body and thus the organ most affected by these materials, including uranium, which leads to damage to the liver tissue, which may develop disease malicious sometimes ^(56,12). as the damage was evident in this study in liver tissue through large changes in the proportions of liver enzymes (AST,ALT) due to the impact of uranium, as well as the change in the proportion of protein and cholesterol, which is greatly large affected by changes that occur in the liver as a result of impaired functions after exposure to this material ⁽⁵⁷⁾, in addition to what was said ^(58,54,33) that exposure to uranium is working on histological satisfactory changes as necrosis of liver cells and damage to the tissue in general. this was also confirmed what was said⁽⁵⁵⁾that hepatic necrosis one of characteristic symptoms after exposure to high concentrations of uranyl acetate.

C- Kidney

The sections of kidneys tissue of animals in the control group have shown that the kidney consist of two layers, the outer layer is called the Cortex containing glomeruli, which is surrounded by Bowman Capsule, The inner layer is called the Medulla that consisting of renal tubules without the presence of the glomeruli (Picture 7). Showed cross-sections of the kidneys of animals in the first group occur conglomerate in the structure of the glomerulus and alienation of some endothelial tissue of the Bowman's capsule, with the advent of expansion of renal tubule that appeared decomposing from the inside with some death of cells(Picture 8). The microscopic examination of the kidneys of animals in the second group showed a bigger effect by increasing the concentration of uranyl acetate that led to the damage to the structure of kidney tissue generally, has been shown to occur large narrowing in the renal tubules, which showed a gap large in the connect to membrane basal, in addition to a significant expansion of the blood vessel and the appearance of RBC which is significantly ,also appeared some cellular death and spread to the inflammatory Cells and the damage was clear in the tissue of kidney (picture 9).

According to many of the research that the kidneys are greatly affected by uranium after the filtration it, which cause damage to this main organ of the organism body and inhibition its functions ⁽⁵⁷⁾, and the kidney is organ of the most sensitive organs to the toxic salts of uranium in humans and mammals in general ^(59,60), and that the high concentrations of this substance lead to kidney failure after large damage to cell membranes and death ⁽¹¹⁾, also noted ⁽¹²⁾ that the non-lethal concentrations of uranium acetate material lead to damage to the kidneys tissues and substantial damage, as well as what was said ⁽⁶¹⁾

about renal damage after the large exposure to uranyl acetate treatment as a result of accumulation in the tissues, which can cause kidney damage in proximal urinary tubule and in the structure of glomerulus by (Nephrotoxisity) ^(63,62), and refer ^(67,66) that the uranyl ion works to inhibit the transmission of sodium and disrupt the process of oxidative phosphorylation occurs in mitochondria of the proximal renal tubules cells and constantly exposed to concentrations of this substance lead to a crash of large blocks of kidney cells, and necrosis of the endothelial cells of tubules with the emergence of large pathological changes in glomerulus ^(56,58), in addition to what was said ^(65,64) that this substance works to block the action of antioxidants to remove free radicals from the kidney cortex causing necrosis of renal cell carcinoma and damaged the glomerulus tissue component and the occurrence of a programmed cells death (Apoptosis), addition to necrosis of the cells lining the renal tubules, which led to weaken the transport which causes impaired renal function in filtering the blood ⁽⁴²⁾, also referred some of the research that the diagnosis of pathological symptoms in the kidneys can be detected within a few days after exposure to uranium in the study of the miners and indicated occurrence of necrosis in the cells of twisted tubules with significant changes in the composition of glomerular of kidney causing weakness filtration kidney ^(41,40), confirmed this also ⁽⁶⁸⁾ that the symptoms become the largest continuously after uranium exposure, resulting in the installation of kidney degeneration and damage to the lining of the tubule and renal histological generally.

(Table 1) The Physiological blood parameters for the treated rabbits with Uranyl acetate.

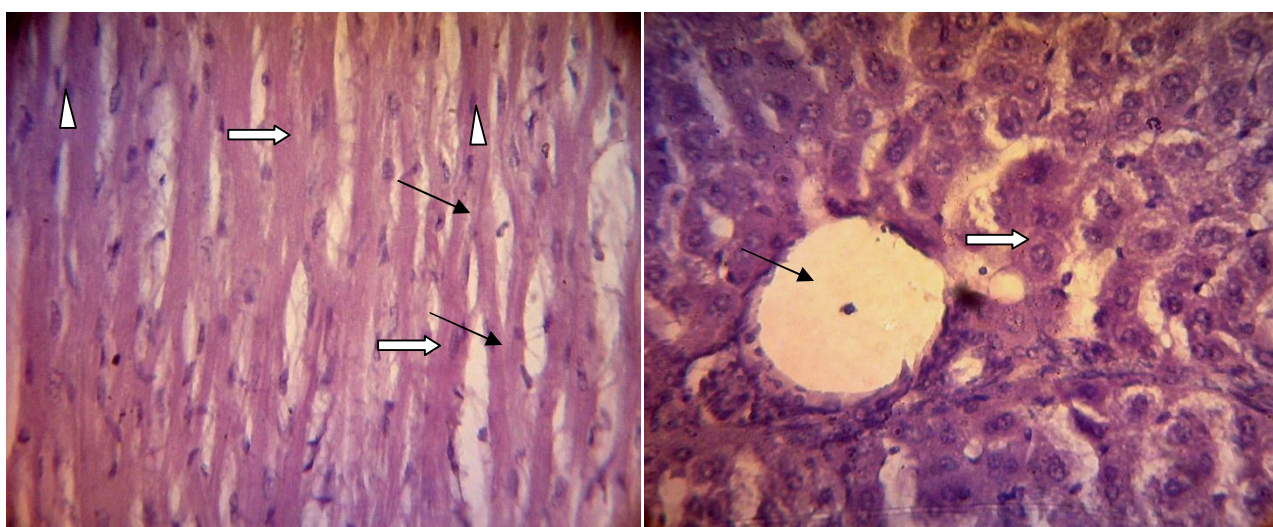
Physiological Tests	Groups		
	Control M \pm SD	G1 M \pm SD	G2 M \pm SD
PCV (%)	46.183 \pm 0.664	43.350* \pm 0.595	40.850* \pm 1.172
Hb (g/dl)	13.100 \pm 0.334	13.316 \pm 0.549	15.283* \pm 0.503
RBC ($\times 10^6$ /ml)	7.001 \pm 0.074	6.766 \pm 0.480	6.100* \pm 0.141
WBC ($\times 10^3$ /ml)	3.566 \pm 0.595	4.283* \pm 2.364	7.350* \pm 1.477

M: the arithmetic mean, SD: standard deviation, the number of animals per group (6), G1: The first treatment group, G2: second treatment group, (*):significant difference ($P < 0.05$) when compared to the control group

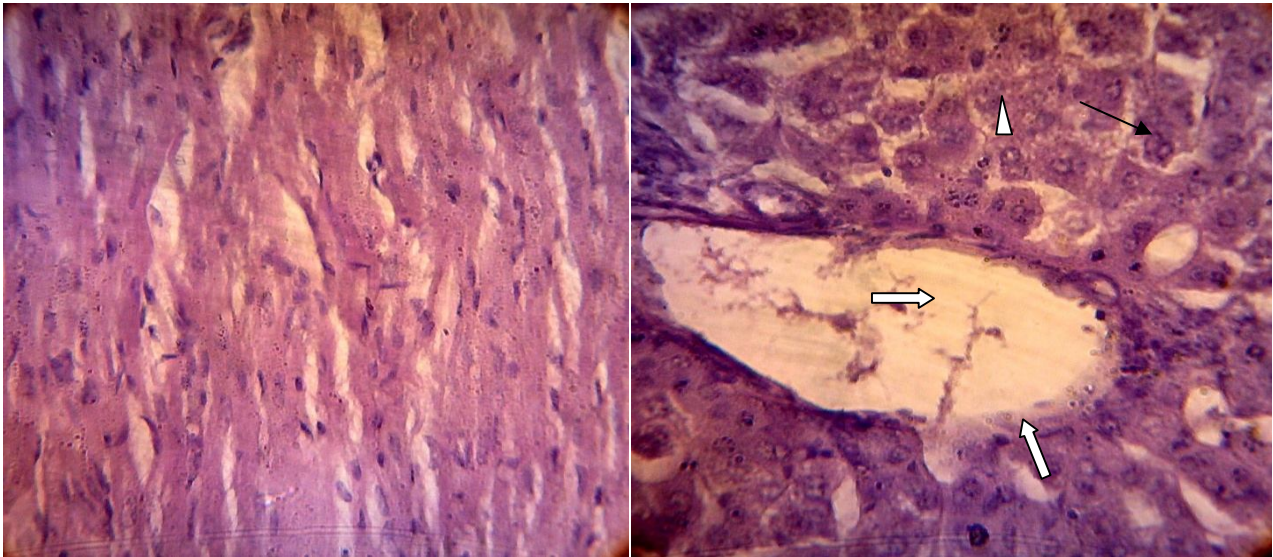
(Table 2) The Biochemical blood parameters for the treated rabbits with Uranyl acetate.

Biochemical Tests	Groups		
	Control M \pm SD	G1 M \pm SD	G2 M \pm SD
T. G	56.50 \pm 6.08	102.81* \pm 27.03	137.47* \pm 40.49
Cholesterol	8.55 \pm 0.56	24.44* \pm 7.79	34.70* \pm 11.35
B. Urea (mg/dl)	35.47 \pm 7.16	63.26* \pm 10.09	71.54* \pm 11.78
Creatinine	0.71 \pm 0.03	1.48* \pm 0.13	2.57* \pm 0.55
AST\ GOT (μ / L)	56.88 \pm 7.75	100.81* \pm 15.14	141.51* \pm 43.08
ALT\ GPT (μ / L)	39.22 \pm 4.81	125.16* \pm 7.79	159.111* \pm 9.10
B. Sugar (Mg/dl)	98.166 \pm 8.084	177.330* \pm 33.770	192.502* \pm 26.430
T. Protein	6.80 \pm 0.38	4.10* \pm 0.21	3.22* \pm 0.52

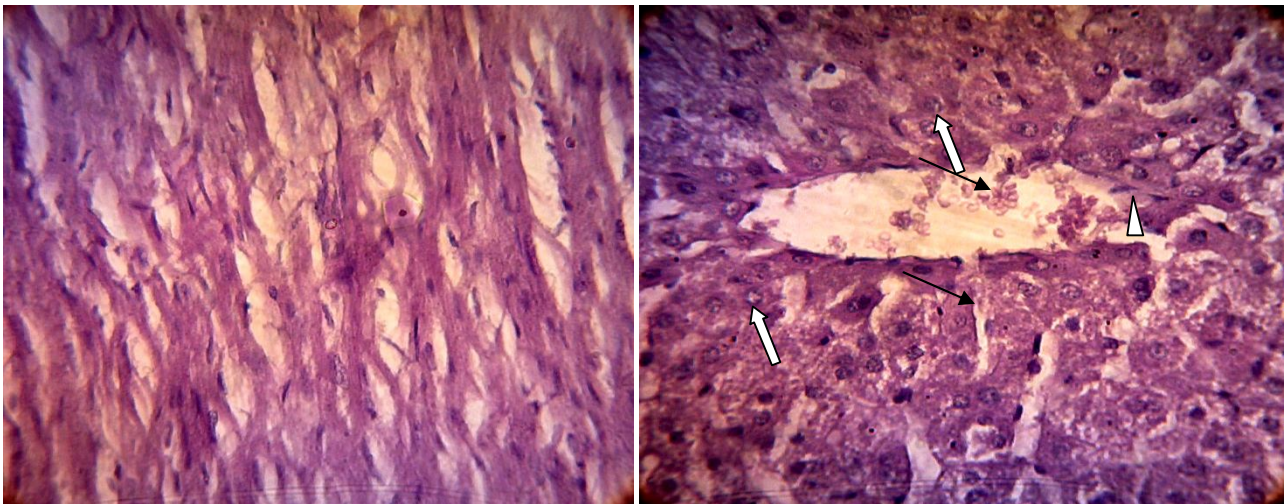
M: the arithmetic mean, SD: standard deviation, the number of animals per group (6), G1: The first treatment group, G2: second treatment group, (*):significant difference (P <0.05) when compared to the control group




(Pictures 1) The heart of control group, **Right** : Cross sections showed large blood vessel(Black arrow) ,Nuclei (White Arrow) . **Left** : Longitudinal section showed Longitudinal & branched cells (White Arrow), Intercalated discs (Black arrow), Nuclei(Arrowhead).(H & E 40X)



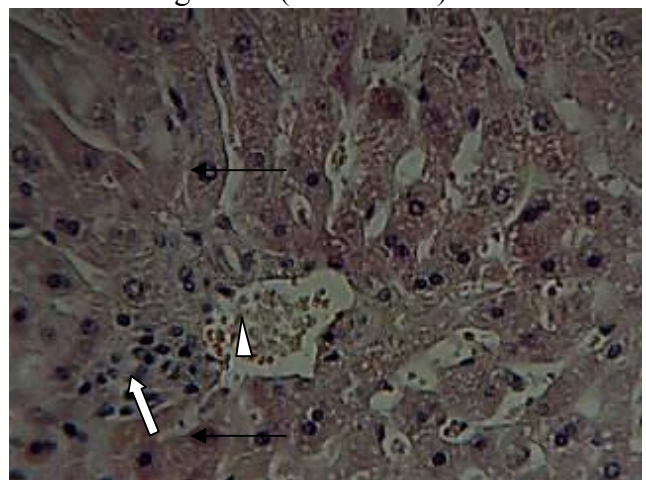
(Pictures 2) The heart of first group, **Right:** Cross sections showed expansion & sloughing of blood vessels (White Arrow), Relapse of Neculous (Black Arrow), Dead cells(Arrowhead) . **Left :** Longitudinal section showed irregular cells & changing the shape of the branching tissue(H & E 40X).



(Pictures 3) The heart of second group, **Right:** Cross sections showed RBC in blood vessel (Black Arrow), Alienation of vessel lining (Arrowhead), Relapse of Nuclei (White Arrow). **Left:** Longitudinal section showed myocardial damage & entire demise in the branching fibers (H & E 40X).

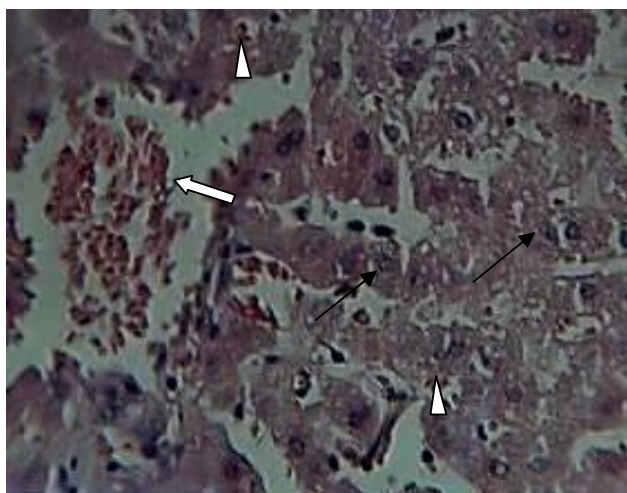


(Picture 4) Cross section of liver in the control group showed Central vain(White Arrow), Hepatocytes (Arrowhead), Radial shape (Black Arrow) (H&E 40X).

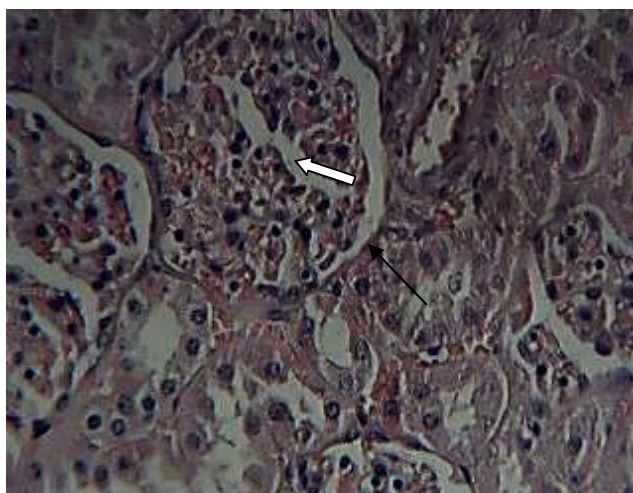


(Picture 5) Cross section of liver in the first group showed Pus cells in the central vain (Arrow head), Damage in cells membranes (Black Arrow) , cells

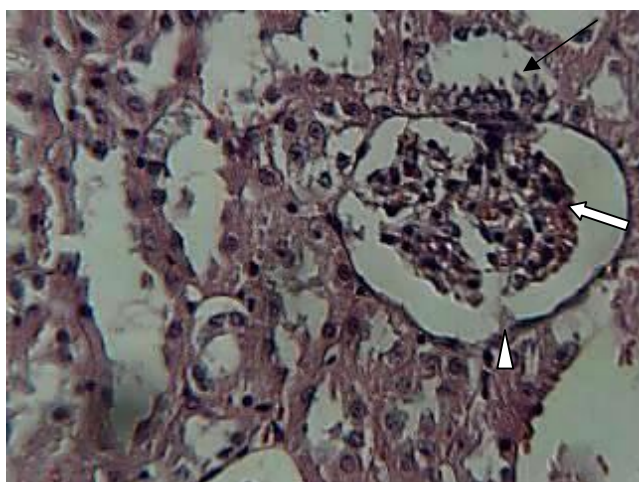
nuclei Conglomerate (White Arrow)(H&E 40X).



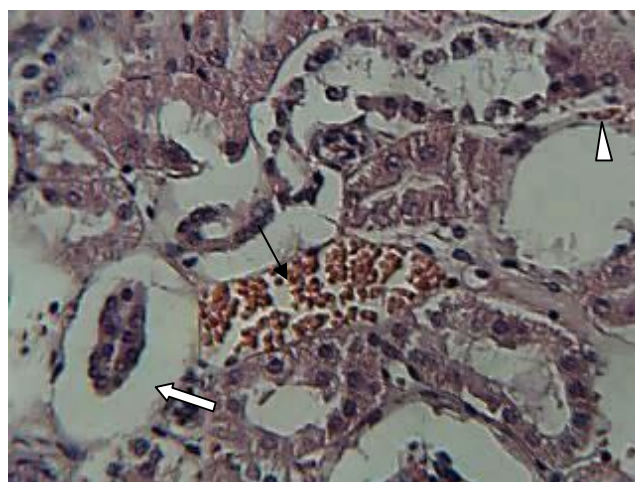
(Picture 6) Cross section of liver in the second group RBCs in central vein (White Arrow) , Dead cells (Black Arrow), Pus cells (Arrow head) (H&E 40X).



(Picture7) Cross section of kidney in the control group showed Glomeruli (White Arrow) , Bowman Capsule (Black Arrow) (H&E 40X).



(Picture8) Cross section of kidney in the first group Showed conglomerate of Glomeruli (White Arrow), Alienation in Bowman capsule (Arrowhead), Renal tubule expansion (Black Arrow) (H&E 40X).



(Picture 9) Cross section of kidney in the second group show narrowing in renal tubules (White Arrow), RBCs in blood vessel (Black Arrow), Cellular death (Arrowhead) (H&E 40X)

تأثير سمية خلاات اليورانيل في انسجة القلب والكبد والكلى
ومعايير الدم الفسلجية والكيموحيوية في ذكور الارانب
م.م. نائل محمد سرheid الحمزاوي كلية الطب \ جامعة المثنى

Nael.serheed@yahoo.com

Abstract الخلاصة

يستهدف البحث الحالي دراسة التغيرات في بعض الانسجة والاختبارات الدموية الفسلجية والكيموحيوية الناتجة من تأثير سمية مادة خلاات اليورانيل باستخدام تركيزين (٢٥ ، ٣٥ ملغم/ كغم) والتي تمثل نسب عالية لاحد املاح اليورانيم ذكرت بعض البحوث ان لها تأثيرات مرضية كبيرة وانها تنتشر في بعض المناطق الموبوءة بهذه المادة ، تضمنت الدراسة استخدام مجموعة من الارانب المحلية

عددها ١٨ حيوان والتي قسمت الى ثلاثة مجاميع ، مجموعة السيطرة : والتي تم تجريعها فمويا ١ مل \كغم من محلول الملح الفسيولوجي (Normal Saline) خلال فترة التجربة البالغة شهرا واحد (٣٠ يوم) ، المجموعة الاولى : جرعت ٢٥ ملغم \ كغم من وزن جسم الحيوان طول فترة التجربة ، المجموعة الثانية : التي تم تجريعها ٣٥ ملغم \ كغم من وزن الجسم خلال فترة التجربة ايضا .

اظهرت نتائج التجربة حدوث انخفاض معنوي ($P < 0.05$) في عدد كريات الدم الحمر(RBC) و حجم الخلايا المرصوص (PCV) ، في حين ظهرت زيادة معنوية في كل من كمية هيموكلوبين الدم (Hb) وعدد خلايا الدم البيض الكلي (WBC) عند المقارنة بمجموعة السيطرة . اما نتائج اختبارات الدم الكيموحيوية فقد كشفت وجود زيادة معنوية ($P < 0.05$) في كل من كمية الدهون الثلاثية (TG) ونسبة الكوليسترول(Cholesterol) واليوريا (Urea) والكرياتينين (Creatinine) في الدم ، كما ظهرت زيادة معنوية ايضا في نسبة انزيمي وظائف الكبد (ALT,AST) وكمية السكر(Suger) في دم حيوانات المجموعتين المعاملتين ، في حين ظهر انخفاض معنوي ($P < 0.05$) في كمية البروتين الكلي(T.Protein) في دم الحيوانات المعاملة عند المقارنة بمجموعة السيطرة للمجموعتين المعاملتين ايضا .

اما في الفحص المجهرى للمقاطع النسجية فقد اظهرت مقاطع النسيج العضلي القلبي حدوث توسع وانسلاخ في بطانة الوعاء الدموي وانتكاس لانوية الخلايا مع ظهور تموت خلوي وتحلل لاجزاء الخلايا ، كما ظهر في المجموعة الثانية تغيرات اكبر تمثلت بظهور نزف كبير لكريات الدم الحمر(RBC) في الوعاء الدموي وانتشار هذه الكريات بين الخلايا مع تلف تام للنسيج . اما المقاطع النسجية للكبد فكشفت عن تضيق في الوريد المركزي ونزف للكريات الحمر (RBC) وتلف لاغشية الخلايا وتكتل لانويتها ، ومع زيادة التركيز ظهر احتقان كبير في الوريد المركزي بالكريات الحمر وتموت الخلايا وظهور خلايا التهابية(Pus Cells). في حين اظهرت مقاطع الكلى تكتل تركيب الكبيبة وانسلاخ بطانة محفظة بومان مع توسع النبيبات البولية وظهور تموت للخلايا ، وبزيادة تركيز الخلات حدث تلف تام للتركيب النسيجي الكلوي مع تضيق كبير في النبيبات وتوسع في الوعاء الدموي وظهور للكريات الحمر(RBC) والخلايا الالتهابية (Pus Cells).

يمكن لنا الاستنتاج من نتائج الدراسة الحالية ان دخول تراكيز عالية من مادة اليورانيم او احد املاحها الى الجسم او حتى التعرض لها في المناطق الموبوءة بهذه المادة يقود الى تأثيرات صحية وجانبية كبيرة يمكن اعتبارها خطيرة جدا على حياة الكائن الحي والتي تمثلت بالتغيرات في تراكيب ووظائف الاعضاء في الجسم والتي اشارت الى مدى الحالات المرضية التي قادت اليها التراكيز العالية المستخدمة في التجربة بعد تعرض الحيوانات لها ، لذلك يجب الحذر بشدة من خطورة هذه المادة.

الكلمات المفتاحية \ خلايا اليورانيل ، السمية ، المقاطع النسجية ، معايير الدم، ذكور الارانب .

References

- 1- Eisem , M. and Gesel , T.I. (1997) . Environmental Radioactivity. Academic press . USA.
- 2- IAEA.(1990).The Environmental behavior for Radium.V(1).Vienna.
- 3-Arabia Authority for Energy . (1996). Bulletin corn and development. Quarterly bulletin quarterly, Tunisia,V(8),N(4).
- 4-Al-Bassam,K.S.(2007).Uranium in the Iraqi phosphorites. Iraqi Bull.Geol. Min., V (3)N(1).13 – 31.
- ٥- عبد القادر، وجدي والقزاز،حكمت والسامرائي،نوري ومهدي ، عبد محمد (١٩٧٦).التحري والتنقيب عن المواد المشعة في الصخور .الفوسفاتية، الرطبة .الشركة العامة للمسح الجيولوجي والتعدين، تقرير داخلي رقم1953 .
- ٦- عبد الفتاح ، هيثم(١٩٧٧).تقرير عن العمل المنجز في منطقة المعانية-واكسة.الشركة العامة للمسح الجيولوجي والتعدين .رقم التقرير ١٦٧٠ .
- ٧- النجم، نجم وعبد الواحد،خالد.(١٩٨٢).المسوحات الراديومترية الاقليمية في الصحراء الغربية (الشاذة .R7) منطقة عكاشات الشركة العامة للمسح الجيولوجي والتعدين . رقم التقرير ١٧٠٠ .
- ٨- العاني ، نزال حسن كاظم و العبيدي ،رياض يونس قاسم واسماعيل زهراء عبد الحسين. (٢٠١١). قياس تراكيز اليورانيم في تربة بعض مناطق ميسان \العراق . مجلة بغداد للعلوم . مجلد ٨(١).

- 9-Belimov, A. A. ;Safronova, V. I. ;Tsyganov, V. E.;Borisov, A.Y. ;Kozhemyakov, A. P.;Stepanok, V. V.; Martenson, A. M.; Gianinazzi-Pearson, V. and Tikhonovich, I. A. (2003). Genetic variability in tolerance to cadmium and accumulation of heavy metals in pea,Euphytica. 131,25–35.
- 10-Meagher, R.B. (2000). Phytoremediation of toxic elemental and organic pollutants. Curr Opin . Plant Biol 3: 153–162 Salt DE, Smith RD, Raskin I (1998). Phytoremediation. *Annu Rev Plant Physiol Plant Mol Biol* 49, 643–668.
- 11-Office of Nuclear Energy,.(1999).Final Programmatic Environmental Impact Statement for Alternative Strategies for the Long-Term Management and Use of Depleted Uranium Hexafluoride. Science and Technology .Department of Energy U.S.A.V(3).
- 12-Hamo,L.M(2006)Scientific Views on the Depleted uranium event corn. World Magazine.Syria.N106.
- 13-Tawfiq, N.F. ; Yas, R.M. ; Alrawi N.B. and Elias,M.M.(2011).Determination of uranium concentration in sheep organs for some Iraqis cities. Baghdad science journal. V(8)3.
- 14 - Lgarashi, W. ; Moss,M.A. and Singh,O.W.(1987).The role of uranium accumulation in different body tissue .Journal of Biological chemistry .173:737-748.
- 15-Wrenn,M.E. Dubrin, P.W. Howard, B. and Lipszten, J.(1985).Metabolism of ingested Uranium health physics.48:601-633.
- 16-Latouche, Y.D. ; Willis. D.L. and Dawydiak, O.I.(1987).Absorption and biokinetic of Uranium in rats following oral administration of Uranyl nitrate solution . Health physics 53:147-162.
- 17-Berlin, M. Uranium in ; Friberg, L., ; Nordberg, G. F. and Rudell, B.(1986).Handbook on the toxicology of metal, 2nd .ed.Amsterdam, Elsevier science publishers.pp.623-637.
- 18-United Nations Scientific Committee on the Effects of Atomic Radiation. (1993). UNSCEAR "Sources Effect, and Risks of Ionizing Radiation", Report to the general Assembly with Scientific Annexes, United Nations.
- 19-Zajic, V.S.(1999). Review of radioactivity , Military Uses and Health Effects of Depleted Uranium.
- 20-Cothorn , C.R. and Lappenbisch, W.L. (1983).Occurrence of Uranium in drinking water in the US. Health physics 45:89-99.
- 21-Dacie, J. and Lewis, S.M.(1974).Practical hematology.Edinburgh. Churchill.Denmark, 6th. Ed.
- 22-Talib, V.(1996). A handbook of medical laboratory technology. WHO.CBS. Publishers and Distributors.,1st ed., p:6-11.
- 23-AL-Omary ,M.R.(1986).Scientific Clinical Chemistry. Technical institutes. First edition.Technico house to Print . Baghdad. Iraq V(76-88).
- 24-Richmond, W.(1973).Preparation and properties of cholesterol oxidase from *Nocardia* sp. And its application to the enzymatic assay of total cholesterol.*Clin.chem.*19:1350-1356.
- 25-Sporin, A.; Dinu,L,stoeneas C.U. and Cirstea, A.(1996). Serum glutamic pyruvic transaminase activity. *Nahrung* 18:572.
- 26-Dawood, K.M. and Ilias, Z.A. (1990). The statistical Methods to Agriculture Researches.AL-Musel University .
- 27-Taha, J. A. ; Abdul_Razak, N.K. and Al-Ali, Z. A.(2009). Some Hematological and biochemical evaluation of sheep reared in areas exposed to Depleted Uranium. Dep. of Animal Resources .C. of Agriculture, Dep. of physiology, C. of Medicine University of Basrah,Basrah,Iraq. Dep.of Biology,C. of Education,University of Missan,Missan,Iraq. Bas.J.Vet.Res.Vol.8.
- 28-Luna, L.G. (1978). Manual of histological staining methods of the armed force institute of pathology . 3rd ed .MC grow hill book . London .
- 29-Fisette,F.D.and Perry,L.I.(1985).Distribution of Uranium in blood,Health physics,USA32:207-211.

- 30-Moss, M.A. (1985). Chronic low level uranium exposure via drinking water, clinical investigation in Nova Scotia. Halifax, Nova Scotia, Dalhousie University (M.Sc. thesis).
- 31-Berradi, H.; Bertho, J.M.; Dudoignon, N.; Mazur, A.; Grandcolas, L.; Baudelin, C.; Grison, S.; Voisin, P.; Gourmelon, P. and Dublineau, I. (2008) Renal anemia induced by chronic ingestion of depleted uranium in rats. *Toxicol Sci.* Jun; 103(2):397-408.
- 32-Gidding, R.C. (1998). Pharmacokinetics models relevant of uranium in human and animals, *Radiation and protection Desimetry*, 26: 243-248.
- 33-Craft, E.S.; Abocari, A.W.; Flaherty, M.M.; Garafolo, M.S. and Abuo-Donia, M.B. (2004). Depleted and natural Uranium: Chemistry and Toxicological effects. *Journal of toxicology and Environmental health Part B, Critical review* 7(4):297-317.
- 34-Jaesckhe, H.; Ho, Y.S.; Fisher, M.A.; Lawson, J.A. & Farhood, A. (1999). Glutathione Peroxidase-deficient mice are more susceptible to neutrophil-mediated hepatic parenchymal cell injury during endotoxemia: Importance of an intracellular oxidant stress. *Hepatology*, 29: 443-450.
- 35-Laker, M. F. (1996). *Clinical Biochemistry for Medical Students*. W. B. Saunders Company, Ltd. PP. 345-349.
- 36-Yoshitani, T.; Yagi, H.; Inotsume, N. & Yasuhara, M. (2002). Effect of experimental renal failure on the pharmacokinetics of losartanin in rats. *Biol. Pharm. Bull.*, 25 (8): 1077-1083.
- 37-Hassan, S. M.; Al-Kenaya, E. R. & Al-Hafez, H. A. K. (2000). Hydrogen Peroxide – Induced Atherosclerosis in Chechens. Effect of Vitamin V. *Iraq Vet. Sci.*, 13:249-270.
- 38-Anthony, M. L.; Gartland, K. P. R. & Beddell, C. R. (1994). Studies of the bio chemical toxicology of uranyl nitrate in the rate. *Arch. Toxicol.*, 68(1):43-53.
- 39-Domingo, J. L.; Liobet, J. M.; Tomas, J. M. & Corblla, J. (1987). Acute toxicity of uranium in rat and mice. *Bull Environ. Contam. Toxicol.*, 39: 168-174.
- 40-Checkoway, H.; Pearce, N.; Crawford-Brown, D. J. and Cragle, D. L. (1988). Radiation doses and cause-specific mortality among workers at a nuclear materials fabrication plant. *Am. J. Epidemiol.* 127:255–266.
- 41-Polednak, A. P., and Frome, E. L. 1982. Mortality among men employed between 1943 and 1947 at a uranium-processing plant. *J. Occup. Environ. Med.* 23:169–178.
- 42-Hao, Y.; Ren, J.; Liu, J.; Luo, S.; Ma, T.; Li, R. and Su, Y. (2012). The protective role of zinc against acute toxicity of depleted uranium in rats. *Asic Clin Pharmacol Toxicol.* V(6):402-10. Epub 2012.
- 43-Morvai, V.; Szakmary, E.; Tatrai, E. & Ungvay, G. (2004). Hemodynamic effect of uranyl acetate in male rats. *CeJoem.* 10(2):149-157.
- 44-Robert, H.; Linda, C. & Lisa, J. (2001). *Outline review clinical chemistry*. McGraw, Medicine Publishing Division, USA, PP 32-40.
- 45-Morvai, V.; Szakmary, E.; Tatrai, E. & Ungvay, G. (2004). Hemodynamic effect of uranyl acetate in male rats. *CeJoem.* 10(2):149-157.
- 46-Domingo, J. L.; Paternain, J. L.; Liobet, H. M. & Corbella, J. (1989). The development toxicity of Uranium in mice. *Toxicol.*, 55(1-2):143-152.
- 47-Mao, Y.; Desmeutes, M. & Schanbl, D. (1995). Inorganic components of drinking water and Microalbuminuria. *Environ. Res.*, 71(2): 135-140.
- 48-Moss, M. A. (1985). Chronic low level Uranium exposure in drinking Water-clinical investigation in Nova Scotia. M.Sc. Thesis Dalhousie University, Halifax.
- 49-Berradi, H.; Bertho, J.M.; Dudoignon, N.; Mazur, A.; Grandcolas, L.; Baudelin, C.; Grison, S.; Voisin, P.; Gourmelon, P. and Dublineau, I. (2008). Renal anemia induced by chronic ingestion of depleted uranium in rats. *Toxicol Sci.* Jun; 103(2):397-408. doi: 10.1093/toxsci/kfn052. Epub 2008.

- 50-**Al-Qaesi, K. S. N. ; Muhmmad M. J. and Ali, L. H..(2013).The study effect of lemongrass oil and effective microorganism (EM) on cholesterol metabolism in rats treated with uranyl acetate C. of Education, C. of Science, Tikrit University, C. of Education for Pure Sciences, Al- Anbar University, Veterinary Anbar J.V(6)N(1).
- 51-**Salih ,Z.A.M. (2001) .Impact of pregnancy and fetus sex on concentration of some enzymes of Arabi ewes serum .Batra .Vet .J .Res.,11:2-9.
- 52-**Tatah, T .J.; Ajam, I.K. and Sial, M.B .(1983).Some factor effecting the hemoglobin concentration of Arabi ewes serum .J.Coll .Educ .,7:49-56.
- 53-**Fisenne, I. M. & Perry, P. M.(1985). Isotopic uranium concentration in human blood from New York city donors. Health phys., 49:1272-1275.
- 54 -** Taylor, D.M. and Taylor, S.K. (1997)Environmental uranium and human health. Rev Environ Health. Jul-Sep;12(3):147-57.
- 55-**Dygert, H. P. ; LaBelle, C. W. ; Laskin, S. ; Pozzani, U. C. ; Roberts, E. ; Rothermel, J. J., Rothstein, A. ; Spiegl, C. J. ; Sprague, G. F., and Stokinger, H. E. (1949). Uranium toxicity following inhalation, eds.C.Voegtlin and H.C.Hodge, vol.1, pp. 423–700. New York: McGraw-Hill.
- 56-**Craft, E.(2004). Depleted and natural Uranium: Chemistry toxilogical effects. J. Toxic. Environ . Health, 7(4):297-0317.
- 57-**Domingo, J. L.; Liobet, J. M.; Tomas, J. M. and Corblla, J. (1987). Acute toxicity of uranium in rat and mice. Bull Environ. Contam. Toxicol., 39: 168-174.
- 58-**Mitrovic, B.; Vitorovie, G.; Jovanovic, M.; Lazarevie-Macanovie, M.; Andrie, V.; Stojanovie, M.; Dakovie, A. and Vitorovi,e D.(2013). Uranium distribution in broiler organs and possibilities for protection. Radiat Environ Biophys. pub.
- 59-**Haley, D.P.; Bulger, R.E. and Dobyan, D.C. (1982).The long-term effects of uranyl nitrate on the structure and function of the rat kidney.Virchows Arch B Cell Pathol Incl Mol Pathol41:181–192.
- 60-**Diamond, G.L.; Morrow, P.E.; Panner, B.J.; Gelein, R.M. and Baggs. R.B. (1989).Reversible uranyl fluoride nephrotoxicity in the Long Evans rat. Fundam Appl Toxicol 13:65–78.
- 61-** Anthony, M. L.; Gartland, K. P. R. and Beddell, C. R.(1994). Studies of the bio chemical toxicology of uranyl nitrate in the rate. Arch.Toxicol.,68(1):43-53.
- 62-**Pellmar, T. C. ;Fuciarelli, A. F.; Ejnik, J. W. ; Hamilton, M., H; ogan, J. ; Strocko, S.; Emond, C. ; Mottaz, H. M. and Landauer, M. R. (1999) Distribution of uranium in rats implanted with depleted uranium pellets. Toxicol Sci. 49: 29–39.
- 63-**Hooper, F. J. ; Squibb, K. S. ; Siegel, E. L. ; Mcphaul, K. and Keogh, J. P. (1999) Elevated urine uranium excretion by sol -diers with retained uranium shrapnel. Health Phys. 77:512–519.
- 64-**Poisson, C. ; Rouas, C. ; Manens, L. ; Dublineau, I. and Gueguen Y. (2014) Antioxidant status in rat kidneys after coexposure to uranium and gentamicin. Hum Exp Toxicol. Feb;33(2):136-47 pub 2013.
- 65-**Homma-Takeda, S. ; Kokubo, T. ; Terada, Y. ; Suzuki, K. ; Ueno, S. ; Hayao, T.; Inoue, T.; Kitahara, K.; Blyth, B.J.; Nishimura, M. and Shimada, Y. (2013) Uranium dynamics and developmental sensitivity in rat kidney. J Appl Toxicol. Jul;33(7):685-94.
- 66-**Leggett, R.W.(1989).The behavior and chemical toxicity of uranium in the kidney arrestment. Health physics.57:93)365-383.
- 67-**Domingo, J.L.(1995).Chemical toxicity of uranium.Toxicology and Ecotoxicology.2(3):74 -78.
- 68-**Agency for Toxic Substances and Disease Registry.(1999). Toxicological profile for uranium (update): Atlanta, GA: Public Health Service.